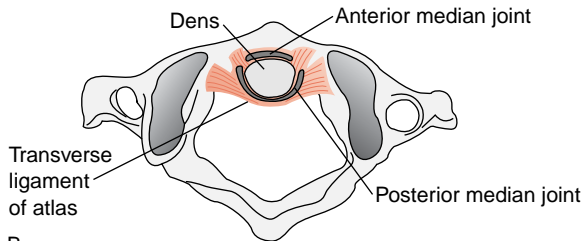


A



B

**FIGURE 24-3.** Atlantoaxial joint architecture. **(A)** Left lateral joint. **(B)** Median joint complex.