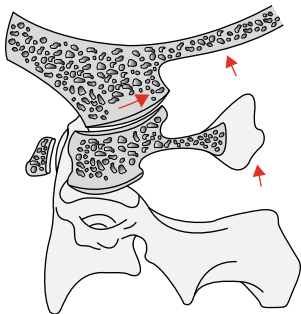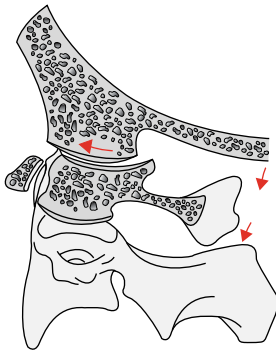
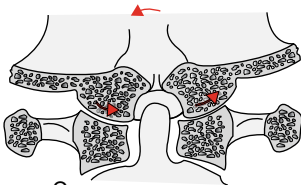


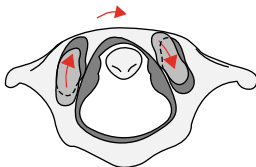
A



B



C



D

**FIGURE 24-2.** Atlanto-occipital joint movement. **(A)** Flexion. **(B)** Extension. **(C)** Left side flexion. **(D)** Conjunct right rotation.